

A PERCUTANEOUS STRATEGY FOR SAFE FEMORAL VENOARTERIAL EXTRACORPOREAL LIFE SUPPORT

To the Editor:

We recently read with interest the article by Vallabhajosyula and colleagues¹ describing their experience with distal limb perfusion in patients requiring peripheral venoarterial extracorporeal life support (VA-ECLS). The authors describe their experience over a 6-year period in 105 patients.¹ In their cohort, there was a nearly even divide among percutaneous cannulation, open cannulation, and no distal perfusion cannulation, with a 26%, 2%, and 20% rate of leg ischemia, respectively. There was no difference in 30-day mortality between groups, and only 1 patient required an amputation.

Distal limb perfusion has been described as the Achilles' heel of peripheral VA-ECLS, with leg ischemia rates ranging between 13% and 20%.²⁻⁴ Although multiple strategies have been advocated, including open cannulation with direct placement of a distal perfusion cannula or sewing a graft to the common femoral artery (CFA), limb ischemia has remained a persistent complication of VA-ECLS.

In their article, Vallabhajosyula and colleagues¹ suggest that a percutaneous approach may be associated with high limb ischemia rates and further recommend lower-extremity angiography in all cases after placement of the distal perfusion cannula. The experience at our center differs: Percutaneous access and placement of a distal perfusion cannula into the superficial femoral artery (SFA) is the preferred technique. After reading this article, we reviewed our VA-ECLS experience over the last 3 years regarding the rate of limb ischemia.

Between July 2013 and June 2016, 102 patients underwent peripheral VA-ECLS with femoral arterial cannulation. The overall rate of limb ischemia in this cohort was 6.8% (7/102). Initially, lower-extremity ischemia was a common morbidity requiring surgical intervention. However, the rate of lower-extremity ischemia over the



past 3 years has decreased from 20% (4/20) in 2013 and 2014, to 6.8% (2/29) in 2014 and 2015, to 1.8% (1/56) in 2015 and 2016. The 1 patient over the past year with lower-extremity ischemia had an extreme vasopressor requirement associated with sepsis, requiring amputation of all 4 extremities, and was likely unrelated to the VA-ECLS cannulation. To effect this reduction, we have instituted several changes in cannulation over the last 3 years. Our current, standardized, approach is as follows: (1) Ultrasound visualization of the CFA, SFA, and profunda femoris artery (PFA) is performed in all cases with confirmation of wire placement in the intended vessel at each subsequent step. (2) Micropuncture sets (Cook Medical, Bloomington, Ind) are used for all arterial access sites. (3a) Access of the SFA is first obtained for the distal perfusion cannula before obtaining access of the CFA for the main arterial return cannula, thereby preventing the arterial return cannula from inhibiting visualization and blood flow to the SFA. (3b) In addition, the SFA distal perfusion site is accessed in a lateral to medial direction, which we believe helps avoid accidental tracking of the wire into the PFA. (3c) After obtaining access to the SFA, we insert the guidewire at least 30 cm into the artery, again ensuring that that the wire has not tracked into the PFA. (4) We now use a 6F wire-reinforced cannula, which we have found to be associated with less leg

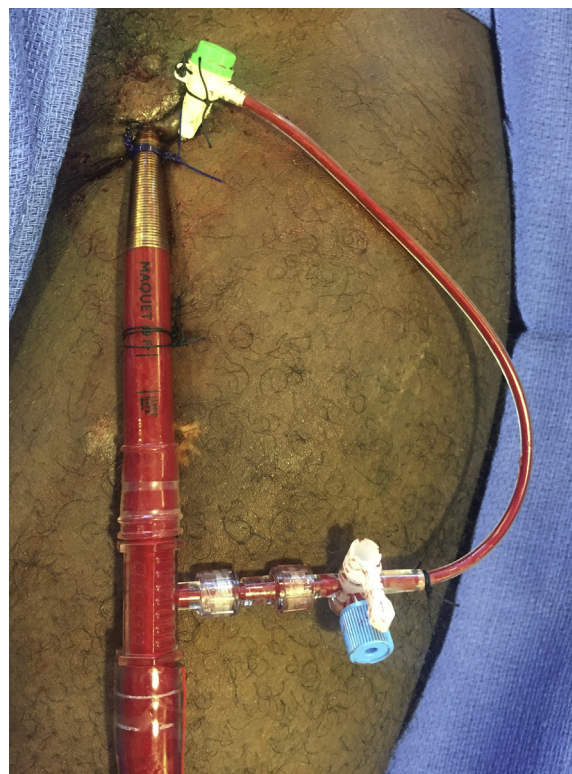


FIGURE 1. Percutaneous approach to femoral arterial cannulation.

The Editor welcomes submissions for possible publication in the Letters to the Editor section that consist of commentary on an article published in the Journal or other relevant issues. Authors should: • Include no more than 500 words of text, three authors, and five references. • Type with double-spacing. • See <http://jtcvs.ctsnetjournals.org/misc/fora.shtml> for detailed submission instructions. • Submit the letter electronically via jtcvs.editorialmanager.com. Letters commenting on an article published in the JTCVS will be considered if they are received within 6 weeks of the time the article was published. Authors of the article being commented on will be given an opportunity of offer a timely response (2 weeks) to the letter. Authors of letters will be notified that the letter has been received. Unpublished letters cannot be returned.

Authors have nothing to disclose with regard to commercial support.

ischemia than the previously used 8F to 10F cannulae. We believe that this small but adequate distal perfusion cannula allows for both forward flow and flow around the cannula into a potentially nonperfused area between the 2 cannulae. (5) Finally, we directly connect the side-arm of the distal perfusion cannula to the arterial return cannula, limiting the length of tubing between the 2 cannulae (Figure 1).

We do not routinely perform open cannulation for access to the SFA or verify flow to the lower extremity via angiography. As stated in the article,¹ this cohort of patients are often critically ill, are in cardiopulmonary shock, and have poor physiologic reserve. Therefore, we believe transport to the operating room for open cannulation and angiography may be imprudent. Furthermore, in our experience, open cannulation is associated with a significant risk of wound infection. With the percutaneous strategy proposed, our rate of ischemia is acceptably low and avoids the potential morbidity associated with transport to the operating room. We advocate bedside, ultrasound-guided, percutaneous cannulation of the SFA with a 6F wire-reinforced distal perfusion cannula.

Chetan Pasrija, MD^a

Michael A. Mazzeffi, MD, MPH^b

Zachary N. Kon, MD^a

^aDivision of Cardiac Surgery

^bDepartment of Anesthesiology

University of Maryland School of Medicine
Baltimore, Md

References

1. Vallabhajosyula P, Kramer M, Lazar S, McCarthy F, Rame E, Wald J, et al. Lower extremity complications with femoral extracorporeal life support. *J Thorac Cardiovasc Surg.* 2016;151:1738-44.
2. Mohite PN, Fatullayev J, Manuz O, Kaul S, Sabashnikov A, Weymann A, et al. Distal limb perfusion: Achilles' heel in peripheral venoarterial extracorporeal membrane oxygenation. *Artif Organs.* 2014;38:940-4.
3. Doll N, Kiaii B, Borger M, Bucarius J, Kramer K, Schmitt DV, et al. Five-year results of 219 consecutive patients treated with extracorporeal membrane oxygenation for refractory postoperative cardiogenic shock. *Ann Thorac Surg.* 2004;77:151-7.
4. Combes A, Pascal L, Luyt CE, Bonnet N, Trouillet JL, Leger P, et al. Outcomes and long-term quality-of-life of patients supported by extracorporeal membrane oxygenation for refractor cardiogenic shock. *Crit Care Med.* 2008;36:1404-11.

<http://dx.doi.org/10.1016/j.jtcvs.2016.08.051>



ACHIEVING SAFE AND EXPEDITIOUS DISTAL LIMB PERFUSION IN FEMORAL VENOARTERIAL EXTRACORPOREAL LIFE SUPPORT



Reply to the Editor:

We appreciate the letter of Pasrija and colleagues regarding our recently published article investigating lower extremity complications after femoral access for extracorporeal membrane oxygenation (ECMO).¹ As hospitals develop more aggressive and mature extracorporeal life support programs, ECMO use will continue to increase. The establishment of safe protocols for preserving distal limb perfusion is therefore imperative.

In their letter, Pasrija and colleagues briefly recount their past 3-year experience with patients who underwent peripheral venoarterial ECMO. They describe a 7% complication rate, which is commendable. As they state, distal limb malperfusion has been cited as the Achilles' heel of peripheral venoarterial ECMO support.² In their detailing of their institution's approach to percutaneous access of the superficial femoral artery, it is implied that this approach has been used in all settings during the past 3 years. At our institution, whenever technically possible we use a similar strategy to achieve percutaneous access for a distal limb perfusion catheter. Whether we use the hybrid operating room, cardiac catheterization laboratory, or intensive care unit (using bedside fluoroscopy), we have adopted a more aggressive approach toward angiographic confirmation of proper catheter positioning.

In addition, there are several frequent clinical scenarios that in our opinion preclude the bedside approach to percutaneous superficial femoral artery (SFA) access described by Pasrija and colleagues. For one, in our study one-third of the patients were placed on ECMO in the setting of cardiac arrest and while undergoing full cardiopulmonary resuscitation. In this setting, we believe that the highest priority is to initiate ECMO flow as expeditiously as possible. We place the large-bore venous and arterial catheters for venoarterial ECMO flow and initiate full ECMO support. We then address the distal limb perfusion cannula once stable ECMO flows have been achieved. In our experience, it is often difficult to achieve percutaneous access with the large-bore femoral arterial cannula in place, which mandates an open approach in these instances. Also, these patients are typically receiving very high doses of inotropic and pressor support. We have found that typically the SFA is severely vasoconstricted in these situations, making bedside access and percutaneous placement more precarious. In the case of patients who require venoarterial ECMO support and have suitable hemodynamics to permit careful placement of the distal perfusion cannula first, we do prefer the percutaneous